


Provided for non-commercial research and education use.
Not for reproduction, distribution or commercial use.



This is an open access article which appeared in a journal published by Elsevier. This article is free for everyone to access, download and read.

Any restrictions on use, including any restrictions on further reproduction and distribution, selling or licensing copies, or posting to personal, institutional or third party websites are defined by the user license specified on the article.

For more information regarding Elsevier's open access licenses please visit:

<http://www.elsevier.com/openaccesslicenses>



Contents lists available at [ScienceDirect](#)

AAACE Clinical Case Reports

journal homepage: www.aaaceclinicalcasereports.com



Case Report

Bilateral Charcot Neuroarthropathy in Pregnancy: A Case Report and Review of the Influence of Pregnancy Hormones on Ligament Laxity



Rebecca Rogers, MBBS, MRCP¹, Ketan K. Dhatariya, MBBS, MSc, MD, MS, PhD^{1, 2, *}

¹ Elsie Bertram Diabetes Centre, Norfolk and Norwich University Hospitals NHS Foundation Trust, Colney Lane, Norwich, Norfolk, United Kingdom

² Norwich Medicine School, University of East Anglia, Norwich, Norfolk, United Kingdom

ARTICLE INFO

Article history:

Available online 28 November 2020

Key words:

diabetes mellitus
Charcot neuroarthropathy
pregnancy

ABSTRACT

Objective: To describe the case of a woman with long-standing poorly controlled type 1 diabetes mellitus who developed bilateral Charcot foot while pregnant. To the best of our knowledge, this is the first reported case of this condition in pregnancy.

Methods: We performed a retrospective review of physical paper medical records; electronically held laboratory results, including glycated hemoglobin; and imaging reports, including plain radiographs and magnetic resonance imaging.

Results: The Charcot feet were treated by standard offloading in total-contact casts or below-knee removable walking boots. As 1 side resolved, the patient was stepped down into normal footwear on one side and a below-knee walking boot on the other. A review of the literature suggests that the increase in ligamentous laxity associated with a rise in circulating hormones, such as relaxin, increases the risk of developing Charcot neuroarthropathy.

Conclusion: Bilateral concurrent Charcot neuroarthropathic foot is uncommon, and to our knowledge, this is the first reported case in pregnancy. We present a possible explanation for why there is an increased risk for the development of Charcot neuroarthropathy in pregnancy.

© 2020 AAACE. Published by Elsevier Inc. This is an open access article under the CC BY-NC-ND license (<http://creativecommons.org/licenses/by-nc-nd/4.0/>).

Introduction

Charcot neuroarthropathy (CN) is an uncommon condition occurring as a complication of diabetes-related peripheral neuropathy. It is characterized by relatively painless fractures and dislocations of the bones of the foot. If CN is not identified and managed early, it may lead to irreversible joint deformity, ulceration with or without infection, and ultimately, lower limb amputation.¹ It has been suggested that once diagnosed, individuals with CN have an 8-year mortality rate of 29% to 40%, with a mean reduction in life expectancy of 14 years.¹ The incidence of CN in people with diabetes has been quoted at 0.1% to 0.2%, with bilateral CN being much rarer, in 12% of cases.^{2,3}

Abbreviations: CN, Charcot neuroarthropathy; MRI, magnetic resonance imaging; TCC, total-contact cast.

* Address correspondence and reprint requests to Dr Ketan K Dhatariya, Elsie Bertram Diabetes Centre, Norfolk and Norwich University Hospitals NHS Foundation Trust, Colney Lane, Norwich, Norfolk, UK NR4 7UY.

E-mail address: ketan.dhatariya@nnuh.nhs.uk (K.K. Dhatariya).

We report the case of a woman with type 1 diabetes mellitus who developed bilateral CN during pregnancy. We propose that pregnancy be added to the list of potential risk factors for the development of CN.

Case Report

A 24-year-old Caucasian woman with a 14-year history of type 1 diabetes mellitus was diagnosed with right foot CN. She recounted a 10-week history of right ankle pain for which she could recall no trauma or trigger. Plain imaging and ultrasound of her foot and calf at the time was reported as normal.

Despite frequent diabetes clinic attendance, her mean glycated hemoglobin reading over the preceding 7 years was 11.6% (103 mmol/mol), with a peak reading of 17.2% (164 mmol/mol) 2 years prior. Previously, she had undergone bilateral pan-retinal laser photocoagulation for proliferative diabetic retinopathy and had microalbuminuric diabetic nephropathy.

On examination, she had a warm, tender, and swollen right ankle. Based on this and her history of poor glycemic control and

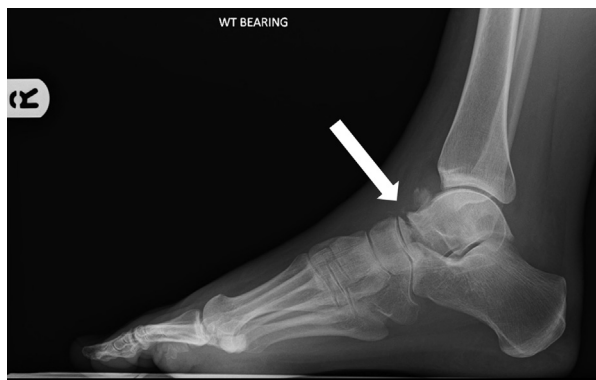

Fig. 1. Lateral plain, weight-bearing radiograph of the right foot and ankle showing an ill-defined osseous body anterosuperior to the talus with a displaced fracture through the anterior aspect of the talus (arrow). There is also bony resorption and callus formation at the fracture margin. WT = weight.

microvascular complications, CN was assumed and offloaded in a removable walker boot.

Plain radiographic imaging of the right ankle joint confirmed a displaced talar fracture with bony resorption (Fig. 1). CN was confirmed and the foot offloaded in a below-knee total-contact cast (TCC). Magnetic resonance imaging (MRI) of the right foot and ankle confirmed CN (Fig. 2 A and B) by demonstrating significant resorptive collapse of the talar head with marked marrow edema in the neck. There was also marked edema of several other midfoot bones and the small muscles of the foot. Offloading in a TCC was continued.

The temperature differences between her 2 feet remained $>2^{\circ}\text{C}$, and she remained in a TCC.⁴ Ten months into treatment with offloading of the right foot, she attended an antenatal clinic at 4 weeks' gestation.

At 20 weeks' gestation, she attended the foot clinic with signs of warmth, swelling, and tenderness of the left midfoot. Because plain radiographs were contraindicated, the diagnosis of bilateral CN was made while awaiting an MRI of the left foot.

While her right foot remained in a TCC, the left foot was offloaded using a below-knee removable boot. MRI of her left foot confirmed early CN (Fig. 3 A and B). She was tried briefly in bilateral below-knee TCCs but found it very difficult to cope. Because she

had been in the right-sided TCC for almost a year (and temperature differences between her 2 feet were no longer relevant), it was felt that despite it being suboptimal for her feet, bilateral below-knee removable walking boots would allow her to cope more easily.

Two weeks after she delivered, she reattended the foot clinic, where her right foot was found to have changed shape, and she was put back into a TCC, with her left foot remaining in a removable below-knee walker. She underwent urgent bilateral foot MRI. These confirmed a reactivation of the right foot CN, and the left foot continued to show soft tissue edema, with no progression of her disease. She had a marked temperature difference between her feet, with the right foot being 5°C warmer than the left. Her right foot remained in a TCC. A further 5 months later, the temperatures between her 2 feet had remained less than 2°C , and plain radiographs showed no changes. Thus, she was stepped down into a removable walker boot on her right foot and normal footwear on her left foot.

Discussion

We present the case of a woman with a 10-year history of poorly controlled type 1 diabetes with multiple end-organ damage. She developed unilateral Charcot neuroarthropathic foot 10 months prior to the start of her second pregnancy, and 4 months into her pregnancy, she developed concurrent contralateral CN.

The pathogenesis of CN is multifactorial, with neuropathic, metabolic, and inflammatory processes overlapping. These result in bone and joint destruction and deformity.¹ The suggestion is that the insensate foot is subject to repetitive trauma and pressure, leading to microfractures and joint and ligament instability.⁵ This leads to deformity, which, coupled with motor neuropathy and distal muscle weakness, causes malalignment of the foot and abnormal biomechanics, with raised plantar pressures. This leads to repetitive microtrauma, resulting in increased perfusion and inflammation. This intraosseous inflammatory response causes localized osteolysis by upregulating osteoclasts, decreasing protective osteoblastic activity and subsequent osteopenia.³ This weakened bone is vulnerable to subluxation, deformity, and further fractures.^{3,5} Additionally, hyperglycemia leads to a cascade of proinflammatory cytokine production, causing endothelial damage and vascular dysfunction.⁶ Hyperglycemia-induced mitochondrial dysfunction has also been suggested to lead to the soft tissue swelling seen in the early stage of the disease.⁷

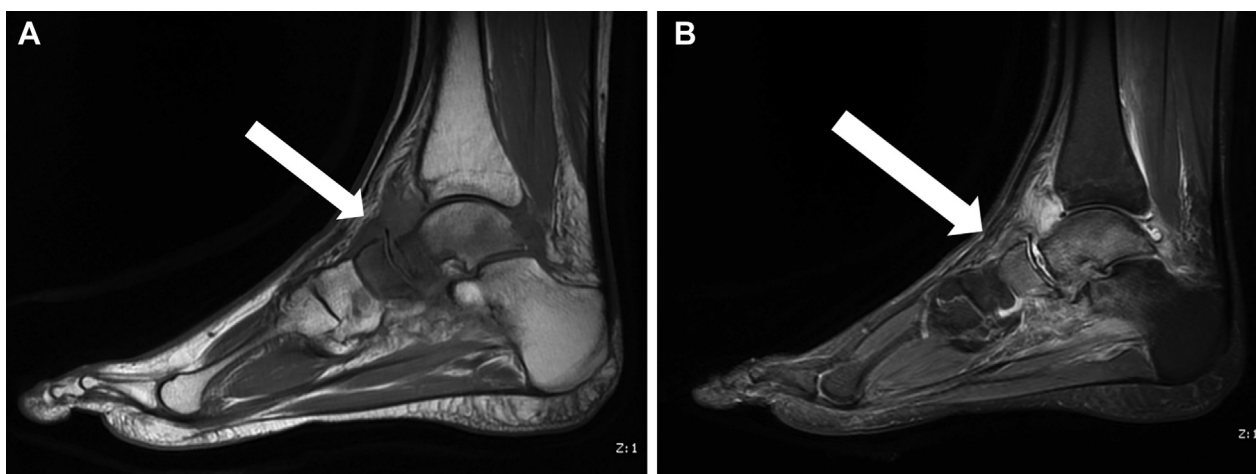


Fig. 2. T1- (A) and T2- (B) weighted magnetic resonance images of the right foot showing a significant resorptive collapse of the talar head with marked marrow edema in the neck (arrows). There is also marked edema of several other midfoot bones and the small muscles of the foot. The differential diagnosis of these presentations is avascular necrosis or CN. CN = Charcot neuroarthropathy.

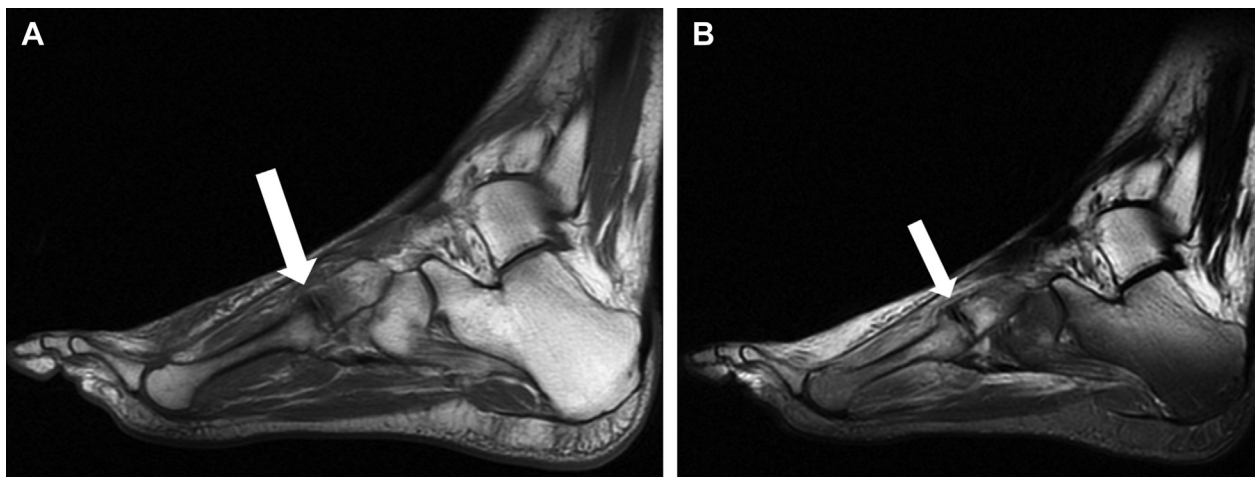

Fig. 3. T1- (A) and T2- (B) weighted magnetic resonance images of the left foot. The arrows show subchondral fractures of the 3rd metatarsal and lateral cuneiform adjacent to the tarsometatarsal joint with extensive surrounding bone and soft tissue edema.

Charcot neuroarthropathic joints are often misdiagnosed as cellulitis, deep vein thrombosis, sprain, or gout.⁸ Anyone with diabetes presenting with a hot, red, swollen, insensate foot (or with pain in a previously insensate foot) should be treated as having CN until proven otherwise and referred to a specialist multidisciplinary foot clinic.⁴ The modified Eichenholtz classification of CN includes a prodromal stage of disease, where there is no plain radiographic evidence of bone damage (Table).⁹ However, MRI has been recognized to show early signs of soft tissue edema, bone marrow edema, subchondral cysts, and microtrabecular fractures.^{3,7}

In addition to a history of diabetes-related foot problems, there are several factors recognized to increase the risk of an individual developing CN. These include obesity, chronic kidney disease, an age over 65 years, Caucasian ethnicity, being ambulant, and the presence of other diabetes-related microvascular complications.¹⁰ To date, pregnancy has not been discussed as a risk for developing CN.

The estrogenic hormones estradiol, estrone, and estriol have been shown to affect the musculoskeletal system, including bone, muscle, cartilage, and tendon composition, elasticity, and strength.¹¹ Estrogen and progesterone receptors have been found in fibroblasts of the human anterior cruciate ligament.¹² It has been postulated that the increased ligamentous laxity seen during the ovulatory phase of the menstrual cycle may be part of the reason why there are gender-specific differences seen in the prevalence of tendon injury and joint disease.¹²⁻¹⁴ In particular, anterior cruciate ligament laxity has been shown to be significantly increased with peak levels of estrogen and progesterone during the menstrual cycle.¹²

Relaxin is a hormone that circulates at low concentrations in the nonpregnant state, but during pregnancy, relaxin is secreted by the corpus luteum and from the placenta. The serum concentrations of relaxin peak in the first trimester of pregnancy. The physiology and feedback mechanism of relaxin is not yet entirely understood, but it

Table
The Modified Eichenholtz Classification of CN

Stage	Findings on plain radiography	Findings on clinical examination	Treatment
0 (prodromal)	Normal	Swelling, redness, and warmth	Ongoing patient education, serial plain radiographs, and protected weight-bearing
I (development)	Osteopenia, fragmentation, and joint subluxation or dislocation	Swelling, redness, warmth, and ligamentous laxity	Protected weight-bearing with a TCC or an off-the-shelf below-knee removable walking boot. Either should be used until radiographic and clinical resolution (ie, resolution of bony fragmentation and a skin temperature difference of <2°C from that of the contralateral foot, for 3 consecutive visits, each at least 2 weeks apart)
II (coalescence)	Absorption of debris, sclerosis, and fusion of larger fragments	Decrease in warmth, swelling, and redness	Protected weight-bearing with a TCC or off-the-shelf below-knee removable walking boot. Either should be used until radiographic and clinical resolution (ie, resolution of bony fragmentation and a skin temperature difference of <2°C from that of the contralateral foot, for 3 consecutive visits, each at least 2 weeks apart). This may be for up to 1 year or more after the initial diagnosis. A Charcot restraint orthotic walker or ankle-foot orthosis may be used
III (reconstruction)	Consolidation of the deformity and joint fusion with fibrous ankyloses and bone fragment remodeling	No evidence of warmth, swelling, or redness. Stable joint with or without a fixed deformity	For those with a plantigrade foot: custom footwear with a rigid shank and rocker bottom sole. For those without a plantigrade foot or continuing ulceration: regular debridement and consideration of surgery, including (but not limited to) exostectomy, deformity correction, and internal fixation

Adapted from Rosenbaum AJ, DiPrea JA (2015).⁹
Abbreviations: CN = Charcot neuroarthropathy; TCC = total-contact cast.

is believed to play a role in promoting the implantation of the developing fetus into the wall of the endometrium by inhibiting uterine contractions. In addition, relaxin activates collagenase and relaxes the ligaments of the pelvic girdle to ease vaginal delivery.^{12,15} Furthermore, it has been reported that there is a significantly higher concentration of relaxin in pregnant women with diabetes compared with those without.¹⁶ Relaxin receptors have been found in a variety of human ligaments and tendons.¹¹ Thus, there may be a link between this hormone and the risk of developing CN in pregnancy.

Of course, what remains unexplained is why, with the many women with poorly controlled diabetes who also have end-organ damage and become pregnant, has CN in this situation not previously been reported. In particular, this could be because many might have developed peripheral neuropathy prior to becoming pregnant. We also speculate that our case may have gone on to develop contralateral CN even if she had not become pregnant, simply because of the added pressure and altered biomechanics of the right foot while she was in her left leg TCC.

Conclusion

We have described the case of a young woman with a long history of poorly controlled type 1 diabetes. She had multiple pre-existing microvascular complications and presented with a unilateral Charcot neuroarthropathic joint. This was treated in a total-contact plaster cast. Ten months later, while still in her cast, she became pregnant and developed a contralateral, concurrent Charcot neuroarthropathic foot. We have suggested a possible etiologic role for relaxin and other hormones. We recommend that clinicians be aware of the possibility of a Charcot neuroarthropathic foot developing in pregnancy.

Author Contributions

K.D. looked after the patient. R.R. wrote the first draft of the manuscript. K.D. wrote the final draft of the manuscript. Both authors reviewed and approved the final submitted manuscript.

Disclosure

The authors have no multiplicity of interest to disclose.

References

1. Jeffcoate WJ. Charcot foot syndrome. *Diabetic Med.* 2015;32(6):760–770.
2. Loupa CV, Meimeti E, Kokas A, Voyatzoglou ED, Donou A. An atypical and bilateral presentation of Charcot foot disease. *BMC Endocr Disord.* 2019;19(1):1–5.
3. Mascarenhas JV, Jude EB. The Charcot foot as a complication of diabetic neuropathy. *Curr Diab Rep.* 2014;14(12):561.
4. Milne TE, Rogers JR, Kinnear EM, et al. Developing an evidence-based clinical pathway for the assessment, diagnosis and management of acute Charcot neuro-arthropathy: a systematic review. *J Foot Ankle Res.* 2013;6(1):30.
5. Kaynak G, Birsal O, Güven MF, Ögüt T. An overview of Charcot foot pathophysiology. *Diabet Foot Ankle.* 2013;4:21117.
6. Chaudhuri A, Umpierrez GE. Oxidative stress and inflammation in hyperglycemic crises and resolution with insulin: implications for the acute and chronic complications of hyperglycemia. *J Diabetes Complications.* 2012;26(4):257–258.
7. Lymbouris M, Gooday C, Dhatariya KK. Mitochondrial dysfunction is the cause of one of the earliest changes seen on magnetic resonance imaging in Charcot neuroarthropathy – oedema of the small muscles in the foot. *Med Hypotheses.* 2020;134:109439.
8. Game FL, Catlow R, Jones GR, et al. Audit of acute Charcot's disease in the UK: the CDUK study. *Diabetologia.* 2012;55(1):32–35.
9. Rosenbaum AJ, DiPrea JA. Classifications in brief: Eichenholtz classification of Charcot arthropathy. *Clin Orthop Relat Res.* 2015;473(3):1168–1171.
10. Fauzi AA, Chung TY, Latif LA. Risk factors of diabetic foot Charcot arthropathy: a case-control study at a Malaysian tertiary care centre. *Singapore Med J.* 2016;57(4):198–203.
11. Leblanc DR, Schneider M, Angele P, Vollmer G, Docheva D. The effect of estrogen on tendon and ligament metabolism and function. *J Steroid Biochem Mol Biol.* 2017;172(9):106–116.
12. Heitz NA, Eisenman PA, Beck CL, Walker JA. Hormonal changes throughout the menstrual cycle and increased anterior cruciate ligament laxity in females. *J Athl Train.* 1999;34(2):144–149.
13. Somerson JS, Isby IJ, Hagen MS, Kweon CY, Gee AO. The menstrual cycle may affect anterior knee laxity and the rate of anterior cruciate ligament rupture: a systematic review and meta-analysis. *JBSJ Rev.* 2019;7(9):e2.
14. Wojtys EM, Huston LJ, Boynton MD, Spindler KP, Lindenfeld TN. The effect of the menstrual cycle on anterior cruciate ligament injuries in women as determined by hormone levels. *Am J Sports Med.* 2002;30(2):182–188.
15. MacLennan AH. The role of the hormone relaxin in human reproduction and pelvic girdle relaxation. *Scand J Rheumatol Suppl.* 1991;88:7–15.
16. Steinetz BG, Whitaker PG, Edwards JR. Maternal relaxin concentrations in diabetic pregnancy. *Lancet.* 1992;340(8822):752–755.