

Case report

QJM

***Rhizobium radiobacter* wound infection in a patient with diabetes—fact, factitious or just plain unlucky?**

K. DHATARIYA¹, C. GOODAY¹, D. MORROW^{1,2}, R. MURCHISON¹, J. TURNER¹,
R. HUTCHINSON^{1,3} and H. WILLIAMS⁴

From the ¹Diabetic Foot Clinic, Elsie Bertram Diabetes Centre, ²Department of Vascular Surgery, ³Department of Orthopaedic Surgery and ⁴Department of Microbiology, Norfolk and Norwich University Hospitals NHS Foundation Trust, Colney Lane, Norwich, Norfolk, NR4 7UY, UK

Address correspondence to Dr K. Dhatariya, Diabetic Foot Clinic, Elsie Bertram Diabetes Centre, Norfolk and Norwich University Hospitals NHS Foundation Trust, Colney Lane, Norwich, Norfolk, NR4 7UY, UK. email: ketan.dhatariya@nnuh.nhs.uk

The case

A 43-year-old man with a 28-year history of type 1 diabetes presented to our foot clinic in February 2008 with a fractured left second proximal phalanx due to trauma. His diabetes control was poor, with an HbA1c of 79 mmol/mol (9.4%) [reference range <42 mmol/mol (<6.0%)] at presentation. He was known to have diabetic peripheral neuropathy, and had previously undergone bilateral pan retinal photocoagulation for proliferative retinopathy. His medications were insulin aspart, and insulin glargine, ramipril, simvastatin, esomeprazole, amitriptyline, aspirin, fluoxetine and indapamide.

He was seen by the orthopaedic team for his fracture and treated with standard offloading. Two months later he was admitted due to ulceration and ascending infection in the same toe. This necessitated digital amputation and intravenous antibiotics.

One month later, he was again admitted with a swollen foot and on X-ray had a fractured proximal phalanx of the hallux. This was initially treated conservatively, but he represented with infection at his surgical wound site. This settled with another course of intravenous antibiotics and a fibreglass backslab while he was an inpatient. He was discharged with his foot in a total contact cast. He was kept under regular review in the diabetes foot clinic.

Three months later, he presented to our podiatry team with a metal foreign body, thought to be a carpentry nail, in the apex of his hallux. He admitted to laying a carpet while in his total contact cast. The distal phalanx showed evidence of osteomyelitis and required amputation.

Over the next few months, he presented with a succession of wounds affecting his left foot and ankle. It was noted that as one was about to heal, another appeared. He eventually presented with what appeared to be an unfolded, broken paperclip in his ankle joint (Figure 1). Neither the patient nor his wife could explain how it got there, and he had never had a surgical procedure at that site. The surgeons felt that these were not appropriate to remove as they were deeply embedded and did not appear to be responsible for his current problems.

His all unusual series of wounds eventually healed; however, in autumn 2009 he presented with pain in his foot. A radiograph showed the presence of a metal foreign body (Figure 2). He claimed to have walked barefoot on a newly laid driveway at a neighbour's house. This object was surgically removed; however, his foot continued to have repeated infections and the patient eventually opted for a below knee amputation.

The wound site was healing well, but he was readmitted a few weeks after his amputation feeling

unwell. At that time his temperature was raised, his white cell count was $12.3 \times 10^9/l$ (reference range $4.0-11.0 \times 10^9/l$), with his neutrophils raised at $10.66 \times 10^9/l$ (reference range $2.0-7.5 \times 10^9/l$), and his C-reactive protein was 125 mg/l (reference range 0-10 mg/l). Because of his multiple previous admissions, and because of the severity of his wound infection, our patient had been treated empirically with intravenous metronidazole, vancomycin and tazocin from the time of admission. His wound

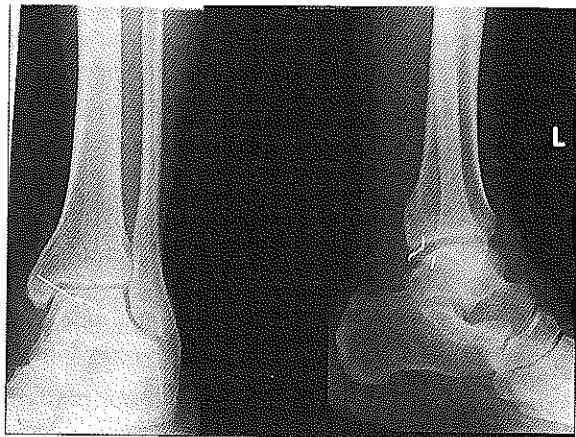


Figure 1. Antero-posterior and lateral radiograph of left ankle showing a metallic object within the ankle joint.

swab grew coliforms, but his blood cultures grew *Rhizobium radiobacter*. His antibiotic regimen led to a resolution of his infection; however, his wound continued to deteriorate, eventually necessitating an above knee amputation.

Six months after his left above knee amputation, he developed a wound on the dorsal surface of his right foot. This was treated with debridement and appropriate podiatric care. However, despite intensive follow-up his foot continued to deteriorate and he required a below knee amputation, almost exactly 1 year following his first below knee amputation on the left.

Discussion

Rhizobium radiobacter (formally known as *Agrobacterium radiobacter*) is a ubiquitous, aerobic, motile, oxidase positive, non-spore forming soil organism. It is usually of low virulence in humans.¹ In many plant species, infection with this organism is known to be associated with neoplastic growth.² While cases of human infection have been previously reported, many of these have been in situations that have provided this organism with an 'ecological niche' that allowed it to flourish. Reports have been published of infections due to contamination of intravenous fluid;^{3,4} in individuals who are

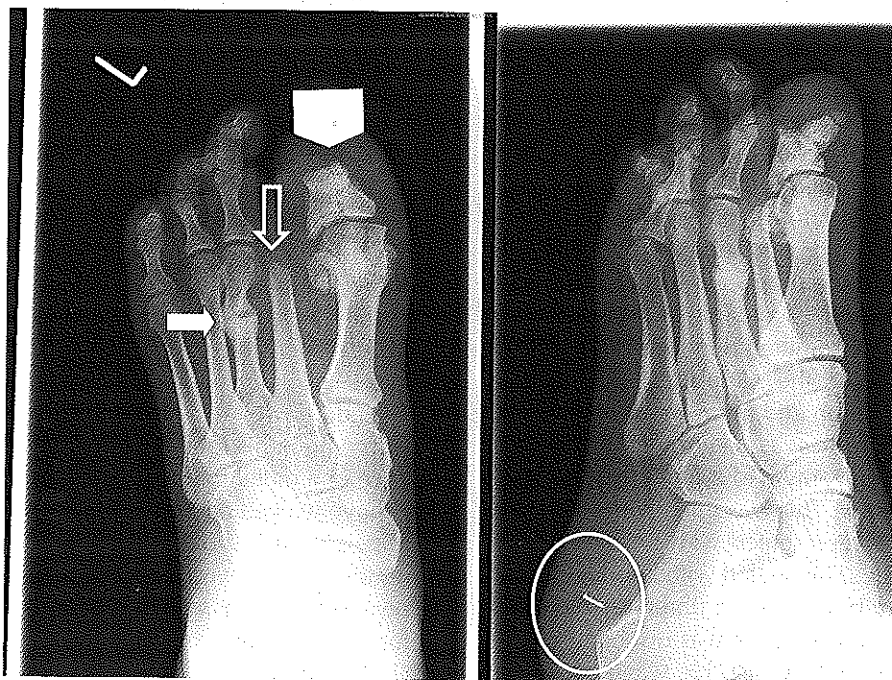


Figure 2. Radiograph of left foot, showing evidence of a healed fracture of the shaft of the third metatarsal (solid arrow), previous amputation of the distal phalanx of the first toe (large arrow head) and second toe (open arrow), and a metallic foreign body (circled).

immunocompromised, often with malignancies or HIV infection;^{1,5-8} or in those people who have indwelling central venous catheters.^{7,9,10} However, no reports have been published of this organism causing an infection or illness in someone with diabetes. Our patient had numerous peripheral intravenous cannulae during his many months as an inpatient, but these were changed regularly according to out of hospital protocol—he had not had one in for more than a few minutes prior to the blood cultures being taken on admission.

Poorly controlled diabetes can represent a form of immunocompromise, with infections being more common in those with diabetes. This is likely to be due to a combination of factors that predispose people with diabetes to infection.¹¹ There are animal and human data to show that hyperglycaemia in circumstances associated with physiological stress may have adverse effects on inflammation, cell injury, apoptosis, endothelial function, the coagulation cascade and platelet aggregation,¹²⁻¹⁴ all of which are necessary for wound healing.

Rhizobium radiobacter has been reported as being sensitive to treatment with third-line cephalosporins, aminoglycosides, fluoroquinolones, extended spectrum beta-lactams and carbapenems.^{1,3,6,15-17} Because of his multiple previous hospital admissions, and because of the severity of his wound infection, we used a very broad spectrum intravenous antibiotic regimen with co-amoxiclav when he first presented to try and cover most of the commonly occurring organisms. This was in the hope that when cultures became available we would rationalize them. The cultures found that he was sensitive to this agent.

Neither we nor the patient are able to explain his numerous successive injuries, or the presence of this highly unusual pathogen in his wound, but he has agreed to the input of a psychiatrist to ensure he does not have an undiagnosed factitious disorder.

Regardless of the cause of his condition, none of the previous literature about human infections with this organism has occurred in a person reported to have diabetes, with no other predisposing conditions. We feel that when an unusual organism is grown, it is important that the wider multidisciplinary team be involved in the discussions as to potential causes, and that the possibility of factitious disease is raised.

Funding

This work was originally presented as an oral presentation at the Diabetic Foot Study Group of the

European Association for the Study of Diabetes meeting at Uppsala, Sweden in September 2010.

Conflict of interest: None declared.

References

- Lai CC, Teng LJ, Hsueh PR, Yuan A, Tsai KC, Tang JL, et al. Clinical and microbiological characteristics of *Rhizobium radiobacter* infections. *Clin Infect Dis* 2004; **38**:149-53.
- Young JM, Kuykendall LD, Martinez-Romero E, Kerr A, Sawada H. A revision of *Rhizobium Frank* 1889, with an emended description of the genus, and the inclusion of all species of *Agrobacterium* Conn 1942 and *Allorhizobium undicola* de Lajudie et al. 1998 as new combinations: *Rhizobium radiobacter*, *R. rhizogenes*, *R. rubi*, *R. undicola* and *R. vitis*. *Int J Syst Evol Microbiol* 2001; **51**:89-103.
- Peiris K, Gee TM, Boswell TC. Bloodstream infection related to heparin infusion caused by *Agrobacterium tumefaciens*. *J Hosp Infect* 2010; **62**:250-1.
- Pereira LA, Chan DS, Ng TM, Lin R, Jureen R, Fisher DA, et al. Pseudo-outbreak of *Rhizobium radiobacter* infection resulting from laboratory contamination of saline solution. *J Clin Microbiol* 2009; **47**:2256-9.
- Edmond MB, Riddler SA, Baxter CM, Wicklund BM, Pasculle AW. *Agrobacterium radiobacter*: a recently recognized opportunistic pathogen. *Clin Infect Dis* 1993; **16**:388-91.
- Christakis GB, Alexaki P, Alivizatos AS, Chalkiopoulou I, Athanasiou AE, Zarkadis IK. Primary bacteraemia caused by *Rhizobium radiobacter* in a patient with solid tumours. *J Med Microbiol* 2006; **55**:1453-6.
- Kato J, Mori T, Sugita K, Aisa Y, Ikeda Y, Okamoto S. Central line-associated bacteremia caused by *Rhizobium radiobacter* after allogeneic bone marrow transplantation. *Transpl Infect Dis* 2009; **11**:380-1.
- Manfredi R, Nanetti A, Ferri M, Mastroianni A, Coronado OV, Chiodo F. Emerging gram-negative pathogens in the immunocompromised host: *Agrobacterium radiobacter* septicemia during HIV disease. *New Microbiol* 2010; **22**:375-82.
- Hulse M, Johnson S, Ferrieri P. *Agrobacterium* infections in humans: experience at one hospital and review. *Clin Infect Dis* 1993; **16**:112-17.
- Chen C-Y, Hansen KS, Hansen LK. *Rhizobium radiobacter* as an opportunistic pathogen in central venous catheter-associated bloodstream infection: case report and review. *J Hosp Infect* 2010; **68**:203-7.
- Sibbald RG, Woo KY. The biology of chronic foot ulcers in persons with diabetes. *Diabetes Metab Res Rev* 2010; **24**(Suppl 1):S25-30.
- Morohoshi M, Fujiswara K, Uchimura I, Numano F. Glucose-dependent interleukin 6 and tumor necrosis factor production by human peripheral blood monocytes in vitro. *Diabetes* 1996; **45**:954-9.
- Jonassen AK, Sack MN, Mjos OD, Yellon DM. Myocardial protection by insulin at reperfusion requires early administration and is mediated via Akt and p70s6 kinase cell-survival signaling. *Circ Res* 2001; **89**:1191-8.

14. Marfella R, Di Filippo C, Portoghese M, Ferraraccio F, Rizzo MR, Siniscalchi M, et al. Tight glycemic control reduces heart inflammation and remodeling during acute myocardial infarction in hyperglycemic patients. *J Am Coll Cardiol* 2009; **53**:1425-36.
15. Plotkin GR. *Agrobacterium radiobacter* prosthetic valve endocarditis. *Ann Intern Med* 1980; **93**:839-40.
16. Mastroianni A, Coronado O, Nanetti A, Manfredi R, Chiodo E. *Agrobacterium radiobacter* pneumonia in a patient with HIV infection. *Eur J Clin Microbiol* 1996; **15**:960-3.
17. Potvliege C, Vanhuynegem L, Hansen W. Catheter infection caused by an unusual pathogen, *Agrobacterium radiobacter*. *J Clin Microbiol* 1989; **27**:2120-2.