

Clinical Conundrums

Pale retinal vessels in newly diagnosed type 2 diabetes

S. Gaur¹, D. Bawden¹ and K. K. Dhatariya^{1,2} 

¹Elsie Bertram Diabetes Centre, Norfolk and Norwich University Hospitals NHS Foundation Trust and ²Norwich Medical School, University of East Anglia, Norwich, UK

Accepted 9 April 2020

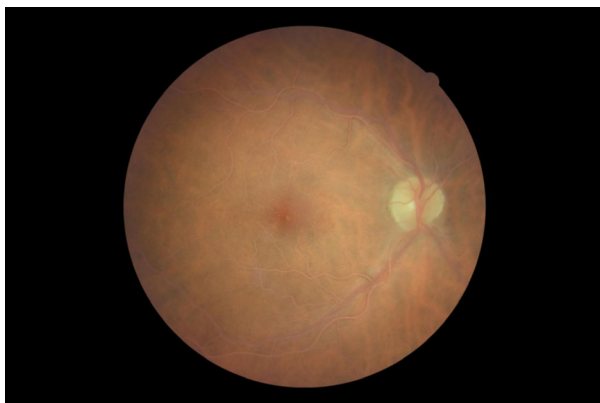


FIGURE 1 Temporal/macular image of right eye at the time of presentation, showing pale retinal vessels.

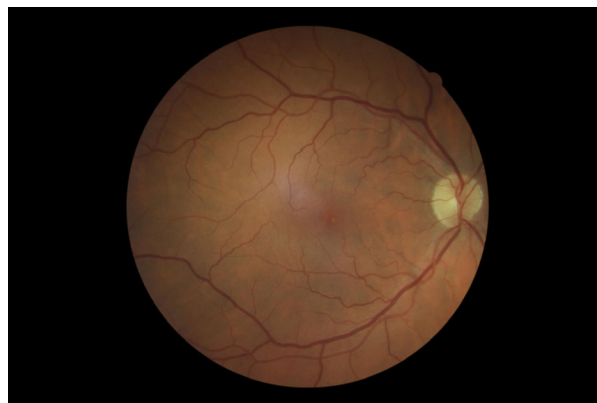


FIGURE 3 Temporal/macular image of right eye, 1 year after presentation, with glycaemic and lipid optimization.

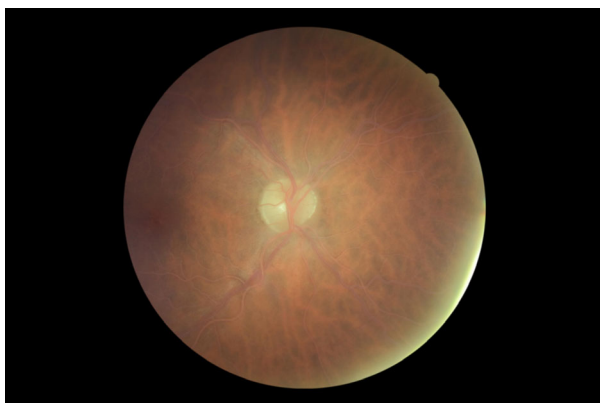

FIGURE 2 Nasal image of right eye at the time of presentation, showing pale retinal vessels.

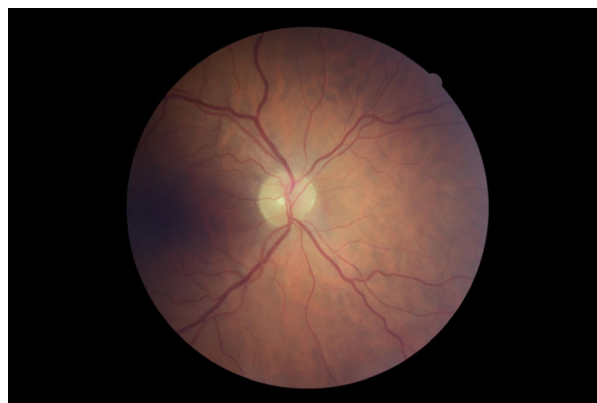


FIGURE 4 Nasal image of right eye, 1 year after presentation, with glycaemic and lipid optimization.

Introduction

A previously well 52-year-old man was seen with a 3-week history of hyperglycaemic symptoms. He had a BMI of 40.8 kg/m², with no evidence of eruptive xanthomas. His random

blood glucose was 19.0 mmol/l (reference range 3.5–6.9 mmol/l), with an HbA_{1c} concentration of 128 (28–42) mmol/mol [13.9 (4.7–6.0)%]. A venous blood sample was reported as being ‘turbid’, with a serum triglyceride level of 128.4 (0.5–1.7) mmol/l. His visual acuity was normal. He was started on twice-daily biphasic insulin and atorvastatin. One month later, his triglycerides were 7.97 mmol/l, with a total cholesterol concentration of 5.9 (3.6–5.0) mmol/l and an

Correspondence to: Prof Ketan Dhatariya.
E-mail: ketan.dhatariya@nnuh.nhs.uk

HDL cholesterol concentration of 0.72 (>1.00) mmol/l. Three months after presentation, his HbA_{1c} level was 41 mmol/mol. His retinal imaging is shown at presentation (Figs 1 and 2) and 12 months later (Figs 3 and 4).

Questions

1. What is the most likely explanation for his retinal findings?
2. What are the differential causes of hypertriglyceridaemia?
3. What is the most frequently described pattern of dyslipidaemia in poorly controlled diabetes, and why is this case?

Discussion (answers)

Question 1

The retinal images of the man's right eye at presentation [temporal/macular image (Fig. 1) and nasal image (Fig. 2)] show lipaemia retinalis. This is a condition characterized by a creamy appearance of the retinal blood vessels attributable to the hyperlipidaemia. This finding is typically only present when the circulating triglyceride concentrations are > 45 mmol/l. It is usually asymptomatic, but there are case reports of reduced visual acuity.

Figure 3 (temporal/macular) and Fig. 4 (nasal) show the retinal vessels of the man's right eye after normalization of the dyslipidaemia with glycaemic optimization and statin use.

Question 2

The causes of hypertriglyceridaemia can be divided into primary and secondary categories [1]. Primary causes are rare, and include a collection of genetic conditions affecting triglyceride metabolism, such as familial dysbetalipoproteinaemia, familial combined hyperlipidaemia, lipoprotein lipase deficiency, apolipoprotein CII deficiency, apolipoprotein CII deficiency, apolipoprotein C-III overproduction, ANGPT3 overproduction and cholesterol ester storage disease.

Secondary causes are more common and include poorly controlled diabetes mellitus, obesity, excessive alcohol consumption, hypothyroidism, pregnancy, obesity, nephrotic syndrome, renal failure, myeloma, systemic lupus erythematosus and drugs including glucocorticoids, tamoxifen, oestrogen and β -blockers. It may be associated with pancreatitis [2]

Question 3

Insulin is required to stimulate the synthesis of lipoprotein lipase inside adipocytes. This enzyme translocates to the endothelium and enhances clearance of lipids (e.g. chylomicrons and very-low-density lipoproteins). If insulin action is impaired or concentrations low, then lipoprotein lipase gene expression is not stimulated, leading to low clearance of these lipid particles. This leads to low concentrations of lipid particles with higher protein content, leading to the classic dyslipidaemia of poorly controlled diabetes: high concentrations of triglycerides, very-low-density lipoproteins and low-density lipoprotein, and low concentrations of high density lipoprotein [3].

Learning points

1. Lipaemia retinalis is a rare ocular manifestation of hypertriglyceridaemia. Although not a sight-threatening condition, it should be considered in people with secondary hyperlipidaemia.
2. Hyperlipidaemia associated with lipaemia retinalis may predispose individuals to other vascular pathologies, including cerebrovascular and cardiovascular events, as well as pancreatitis, and should prompt early treatment.
3. Lifestyle modification, intensive insulin therapy and the use of lipid-lowering therapies may normalize the lipid concentrations and thus the retinal vessel abnormalities. Visual acuity in symptomatic patients also improves.

Funding sources

None.

Competing interests

None declared.

References

- 1 Rymarz E, Matysik-Wozniak A, Baltaziak L, Prystupa A, Sak J, Grzybowski A. Lipemia retinalis - an unusual cause of visual acuity deterioration. *Med Sci Monit* 2012; **18**: CS72–CS75.
- 2 Horton M, Thompson K. Lipemia retinalis preceding acute pancreatitis. *J Am Optom Assoc* 2011; **82**: 475–480.
- 3 Goldberg IJ. Diabetic dyslipidemia: Causes and consequences. *J Clin Endocrinol Metab* 2001; **86**: 965–971.